

Focal Palatine Erosion Associated With Dental Malocclusion in Captive Cheetahs

Helena M. Fitch and David A. Fagan

Research Department, Zoological Society of San Diego, (H.M.F.) and The Colyer Institute, San Diego, California (D.A.F.)

NOTE: Following is a summary of the article appearing in **ZOO BIOLOGY** in 1982. For a complete draft of the article contact authors or your resource library.

A severe palatine disorder caused by maloccluded molars was discovered in captive adult cheetahs at the San Diego Wild Animal Park. This defect has been labeled focal palatine erosion (FPE). Subsequently, a total of 59 cheetahs from several institutions have been examined to evaluate the occurrence and etiology of this disorder. Maloccluded lower molars contacting the palate mucosa appear to be the primary source of irritation. Infection develops when decaying food and grass panicles become lodged in the resulting defect. Eventually, complete palatine perforation results which can extend into the nasal passages and eventually lead to systemic disorders. Focal palatine erosion appears to be a result of dietary factors.

All cheetahs with FPE received a commercially prepared soft diet while in captivity. The lack of normal biting, tearing, and pulling action associated with natural prey capture and consumption could result in malocclusion caused by atrophy from disuse of the masticatory apparatus.

Improper occlusion could also stem from insufficient wear or unsynchronized development of the opposing dental arches. All but two cases of FPE were found in cheetahs imported from a limited area in southwest Africa in 1970, or their offspring. Since molar size and jaw structure can be inherited, there may be genetic factors involved but more data are needed to support this idea. Treatment includes changing diet, reducing the height of the offending molar, controlling infection, eliminating irritants, and in some cases, surgical reconstruction.

INTRODUCTION

The cheetah is one of the most sought after species for public and private zoological collections. Although they were exhibited in London as early as 1829, none were bred in captivity until 1960 [Jones, 1981]. Approximately 30 litters have been born in captivity in the US since 1977. No wild-caught cheetahs have been imported since 1972. Consequently, the remaining wild-caught animals are old and increasingly unsuitable for reproduction [Lindburg, personal communication]. In 1981-1982 we assembled data on 85 cheetahs—59 live individuals and 26 museum skulls.

When our data were assembled and examined collectively, the profile of a developmentally disabling oral condition emerged. This self-inflicted localized wound through the roof of the mouth has been labeled focal palatine erosion (FPE). FPE has been identified in museum specimens, wild-caught individuals presently living in captivity, and in captive-born individuals. This disorder has been associated with diet, specific blood lines, macro nodular renal disease, chronic suppurative rhinitis, and noma.

The implications of this syndrome for a captive breeding program appear to be significant, particularly in light of the fact that the cheetah has very little genetic variation [O'Brien et al, 1981], an aberrant sperm form [Howard et al, 1981], and rather poor reproductive history [Jones, 1981].

Description and Pathogenesis of FPE

The defect identified in this study consists of a self-inflicted wound through the palate, medial to the upper first molars. In all cheetahs there is normally a light indentation of the palatine mucosa in the general area of the greater palatine foramen, apparently to accommodate the predominate distal cusp tip of the lower first molar (Fig. 1).

FPE has been identified as early as 10 months of age (Table 1, case 6). The initial lesion is a slight, localized cellulitis and may be easily overlooked as a typical eruption or "teething" disorder [Levesque et al, 1981].

As the dental cusp tips make regular contact with the palatal mucosa, a destructive circular pattern of mucosal cellulitis with loss of normal mucosal pigmentation occurs. The tooth eventually penetrates through the palatine bone itself, causing further inflammation. Eventually, a localized osteomyelitis occurs as the recurrent trauma compromises the reparative capability of the bony palate.

With continued traumatic impaction of foreign particulate matter into the defect, a gangrenous noma like process [Buchanan et al, 1981] begins to spread throughout the adjacent oral-facial tissues resulting in a large oral-nasal fistulous defect which extends completely through the palatine bone into the nasal passage. destroying the nasal turbinates . In the most severe case, a destructive osteonecrosis progressed all the way up to the bony support of the orbit of the eye, destroying the posterior one third to one half of the nasal turbinates, leaving a fistulous defect between the mouth and the nasal passage. Dental malocclusion of one degree or another has always been observed in association with the tissue damage.

In advanced cases, via the circulatory system, an intermittent chronic bacteremia occurs with all of the associated systemic consequences, such as renal failure, bacterial endocarditis, and bacterial arthritis.

Frequency and Distribution

Analysis of 19 cheetahs fed commercial diets and imported in 1970 from SW Africa, or their offspring, showed a 70% incidence of FPE (Fig. 5). The wild-caught vs captive-born animals were analyzed independently and the figures were unaffected. Analysis of the diet with further consideration to import groups show that all but one affected cheetah were 1970 imports or their offspring. (This analysis excluded one animal of E African origin with FPE.) This disease was absent in 39 cheetahs fed natural diets that were 1972 imports or decedents (Table 2). One animal from the 1972 group received a commercial dia and developed FPE.

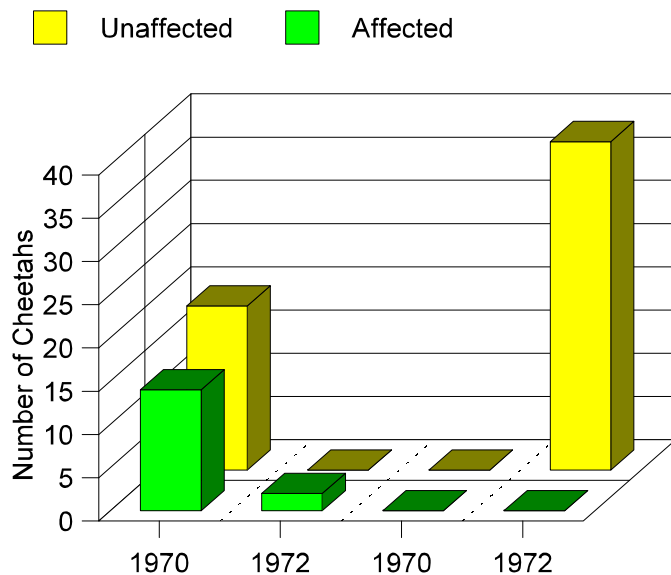
TABLE 1. Oral Examination Data (Live Cheetahs)

I.D.	Sex	Age	Animal's History	Exam Information and Symptoms	Oral Condition
No. 1 Cleo WAP-21	F	7 or 8	Captive born LCS. Parents, 1970 imports.	Routine exam after Quarantine. Severe foul breath	Severe bilateral erosion extending to ocular orbit. Supporting bone absent. 4th PM absent bilaterally and 1st M forward. Cavities filled with decaying grass and foxtails.
No. 2 Sheba WAP-14	F	7 ½	Captive born at WAP. Stolen as cub and returned by unknown person in 1/80.	Blood-tinged mucous discharge from nose, gagging behavior.	Erosion on left side extending through nasal passage. Inflammation from decaying foxtails & twigs. Upper left molar absent.
No. 3 Nyrie WAP-20	F	4	Born and raised at LCS. Breeding loan to WAP, Sept. 1981. Parents 1970 imports.	Routine exam after quarantine.	Erosion on left side extending up to nasal passage. Slight inflammation on right side.
No. 4 Lena LCS-1	F	6	Born and raised at LCS. Parents 1970 imports. Littermate: Naibi	Routine exam.	Erosion on left side. Filled with foxtails, slight inflammation.
No. 5 Naibi LCS-2	F	6	Born and raised at LCS. Littermate: Lena (blind in left eye due to unknown causes.)	Routine exam.	Erosion on left side with loss of pigmentation.
No. 6 Arusha ISIS No. 181008	M	10mos.	Born WLS, sent to SDZ for show animal, 1981. Parents 1972 imports.	Hole through palate observed by keeper.	Deep puncture-type hole on right side, no foreign matter, elongated distal crust. Upper molars absent on right side.
No. 7 Suki ISIS No. 100233	F	15+	Wild caught from E. Africa. Sacramento Zoo since 1977.	Drooling, runny nose licking up food.	Deep abscesses almost to nasal cavity bilateral through palate. Several smaller wounds around edge of palate. More lesions medial to bottom teeth. Infection and bleeding gums. Severe malocclusion.
No. 8 Kigori	F	5	Born at WAP 4/24/75. Milwaukee Zoo since 1976. Parents 1972 imports. Littermate to Gelatt.	Symptoms of oral-nasal problems.	Right mandibular molar. Lesion open to right max. sinus. No cryptococcus.
No. 9 Hermie WAP-8	M	14+	SAP — 1970 import.	Routine exam and postmortem.	Slight erosion, incomplete fistulas, teeth normal.
No. 10 Middleman	M	6	Born at WAP 5/14/76.	Necropsy (examined	Narrow deep hole on left

	WAP-22			Raised at WAP and died of virus disease. Littermate: Sundown.	several months before under sedation and defect was not detected).	side with slight erosion on right.
No. 11	Jillani	F	6 ½	Born at LCS in TX, 11/9/75. Parents 1970 imports. Gladys Porter Zoo until 8/11/76. Presently at SDZ.	Underweight, rough coat. Conjunctivitis & foul breath. Liver damage.	½ x 1 cm leions on left side full of decay and debris.
No. 12	Pepper	F		Born LCS. Parents 1970 imports. Littermate: Cleo.	Postmortem. Died of kidney failure.	Bilateral lesions penetrated completely through the palate on left side. Infection present and full of decayed grass. Lymph nodes swollen.
No. 13	Gelatt WAP-24	M	7	Born at WAP 4/25/75. Cataracts in both eyes, partial. Breeding loan to private party until 5/12/82. Return to WAP. Littermate: Kigori.	Routine exam after quarantine.	Erosion and discoloration bilaterally.
No. 14	Blackfoot	M	14+	1970 import. Kept at WAP.	Postmortem	Lesion on both sides; perforated on left. General dentition normal, middle top incisors absent. Distal cusp on left side blunt.
No. 15	Green	M	14+	1970 import. Kept at WAP.	Postmortem	Slight fistula on left. Molars appear normal. Tips broken off and right canine split up to gumline.

Abbreviations:

WAP—San Diego Wild Animal Park, San Pasqual, California;
 LCS—Lion Country Safari, Irvine, California;
 WLS—Wildlife Safari, Winston, Oregon.



Examination of 26 museum skulls revealed four cheetahs with palatine bone perforation inflicted by the opposing molar. These abnormal skulls were found among eight animals known to be zoo raised (Fig. 6). Fourteen specimens which were wild collected (some as early as the 1930's) did not show evidence of FPE.

Fig. 5. Cheetah's diets and relationship to import group.

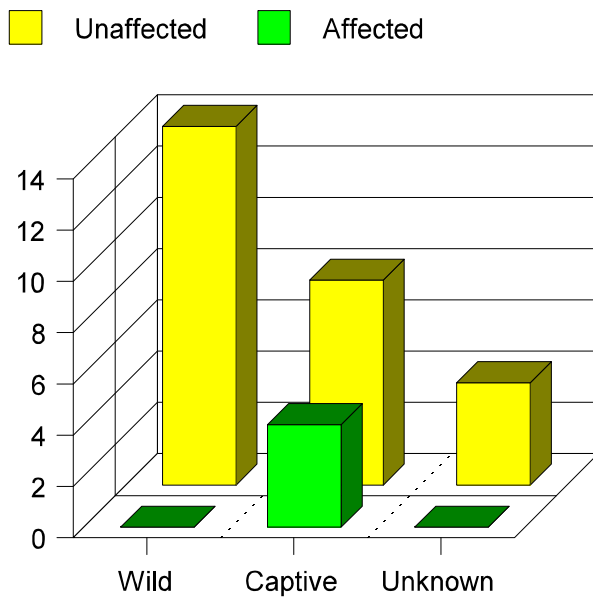


Fig. 6. Museum skull specimens with advanced focal palatine erosion (FPE).

Relationship to Dentition

Focal palatine erosion appears to be caused by maloccluded dentition. In the most severe case (case 1), bilateral lower fourth premolars were missing and there was extreme mesioangular inclination of the lower first molars (Fig. 7). This resulted in an elevation of the distal cusp tip of

TABLE 2. Occurrence of Defect in Individuals Raised at Five Different Institutions

Institution	No. Examined	FPE Cases	Diet
Winston ^a	39	0	Carcass
Other zoos	20 ^b	15	Commercial

^aNote that Winston has 2x as many subjects examined with no occurrence of FPE.

^bIncludes one individual obtained from Winston as a young juvenile.

the lower first molars bilaterally which, in turn, caused that portion of the tooth to make contact with the soft tissue of the palate each time the mouth was closed. This continuous self-inflicted trauma eventually penetrated completely through the palate into the nasal passage. This condition (FPE) was aggravated by the presence of impacted decayed grasses and food debris resulting in considerable further tissue destruction and osteonecrosis.

Accompanying Behavioral Signs

Signs of abnormal behavior or pathology are not always easily observed with this disease, and in some cases, were only discovered during necropsy. In the first severe case observed (case 2), a blood-tinged mucous discharge from the nose was the chief complaint which prompted a comprehensive physical examination. This animal displayed signs of snorting and sneezing in an apparent attempt to dislodge an irritant from the nasal chamber. Examination revealed varying degrees of soft and hard tissue erosion and perforation through the lateral aspect of the palate in the area bounded by the greater palatine foramen, the midline of the palate, and the maxillary left first molar that extended into the nasal passage. The entire posterior nasal cavity was impacted with decaying grasses, necrotic tissue, twigs and several hundred "foxtails" (spiked, flowering grasses). In another individual (case 1), preliminary examination revealed similarly impacted debris in the nasal passage. However, when seen 1 wk later for treatment, the nasal passage was essentially free of debris, suggesting that the sneezing and coughing were effective.

Relationship to Renal Failure

Radiographs of the mandible of case I [using the method of Zontine, 1975] were examined, revealing medullary osseous tissue which lacked the latticelike trabeculation patterns of characteristic of healthy osseous structures, and which is suggestive of a systemic bony disorder or atrophy from disuse of the masticatory apparatus. Spolnick, et al [1981] discuss the radiographic manifestations of renal disease and point out that a number of systemic diseases have oral manifestations, but unfortunately many of their radiographic appearances are not

characteristic for a particular disease. The radiographic changes associated with renal osteodystrophy include subperiosteal bone resorption, altered jaw density, localized destructive lesions, tooth abnormalities, and extraneous calcifications. The necropsy report of the cheetah described in case 12 associated the cause of death with severe kidney failure which was accompanied by chronic suppurative lymphadenitis associated with the oral-nasal osteomyelitis and FPE.

DIAGNOSIS, CONTROL, AND TREATMENT

Focal palatine erosion is diagnosed by direct visual observation of the lesion and lower first molars. Early lesions are characterized by chronic localized cellulitis and the five classic signs of inflammation. It is possible that alteration of the normal blood chemistry may indicate a lesion in a general and nonspecific manner. More severe lesions are associated with specific osseous changes and chronic bacteremia. Consequently, any effective screening method for renal osteodystrophy could prove to be diagnostic for FPE.. Spolnick et al [1981] suggest that "dental and hand radiographs would be the safest and most efficient means of screening patients for renal osteodystrophy, because of their high diagnostic potential" Zontine [1975] and others have adequately described the appropriate radiographic techniques. Marshall [1976] has correlated the relationship between oral radiographs and both dental development and skeletal development (hand and wrist), which may be of help in interpreting intra-oral radiographs in exotic species. Smuts et al [1978] discuss in detail the eruption sequence of deciduous and permanent teeth in large felids.

FPE was initially treated with appropriate systemic antibiotics to manage the ever-present localized cellulitis and bacteremia. Page and Schroeder [1982] note that the tetracycline derivative minocycline is one of the most effective antibiotics for the treatment of periodontal infections because it reaches concentrations in the gingival fluid approximately fivefold higher than in the blood. Decaying grasses, food, and other debris were removed from the nasal passage, and the entire defect area flushed, debrided, and treated with a local bacteriostatic agent. The first cheetah (case 2) treated also displayed symptoms of severe allergic rhinitis, that did not respond to treatment until the patient was relocated onto a concrete-floored enclosure free from grass.

Less severe cases were treated by reducing the tip of the offending dental cusps (see Fig. 9), medicating the exposed pulpal tissues, restoring the biting surface, and prescribing antibiotics to encourage soft tissue repair and regeneration. The surgical knowledge required to repair the oral-nasal defect is readily available and, although the task represents a significant commitment in time and expense, reconstruction is possible with a repositioned tissue graft. The graft site should be evaluated post-operatively for healing and scheduled for follow-up as necessary.

DISCUSSION

Dietary Cause

Malalignment of the dentition could be the result of trauma during the development of the teeth and/or masticatory apparatus. or from other developmentally related causes like nutritional

imbalance, dietary deficiency, or simply atrophy caused from disuse [Tiecke et al, 1959]. However, Melhop's [1982] investigation suggests that most morphological differences observed between wild and captive carnivores are environmental, rather than genetic in origin [personal communication!]. Diet is clearly an environmental factor. The recent work by Corruccini and Beecher [1982] reveals that a group of 43 squirrel monkeys raised on soft foods show more rotated and displaced teeth, crowded premolars, and absolutely and relatively narrower dental arches. They further conclude that chewing stress is an epidemiological factor with possible preventive implications for occlusal disorders, and that relation of masticatory demand to processed foods provides a consistent model for predicting the inevitable transition from predominantly good to bad human occlusion *within one generation's time*, as experienced by many societies when the diets shift to soft, processed foods (emphasis added).

All of the live animals in our study that exhibited FPE were raised on a soft, commercially prepared diet. Although occasional bones were provided in some cases, the authors observed that cheetahs showed little interest in chewing on them unless quite a bit of meat was still attached. In no case were they observed using their molars. These cheetahs may also not have been provided with the proper masticatory stimulus during their developmental period, which could have resulted in the abnormal dentition at maturity. The affected cheetahs may have experienced changes in their jaw structure such as those described by Hollister [1917] and Melhop [1982]. The physiology of exercise and the impact of regular exercise upon the mammalian skeletal muscular system are important developmental factors. The most significant item noted when observing cheetahs ingesting a soft commercially prepared carnivore diet is the lack of vigorous tearing and chewing exercise associated with the eating or gulping behavior.

The masticatory apparatus of the carnivore has been designed and perfected by strenuous use for a long period of time. Rapid loss of muscle strength and tissue mass appear to be associated with a regular diet of soft food. It is possible that cheetahs require additional "hassle factor per mouthful of nutrients" [Fagan, 1980 a, b], not just to sustain their normal levels of facial muscle mass, but to prevent the development of oral defects. A case of dental malocclusion and focal palatine erosion in a clouded leopard was recently seen at the San Diego Zoo and suggests that other species may be similarly affected as well.

In 1917, Hollister at the National Zoo described some effects of environment on a group of over 100 East African lions. He contrasted the zoo animals with a similar group of wild-killed specimens and found definite differences in their skulls. The captive lion skulls were shorter, broader, and massive in structure. Hollister believed the changes were the result of atrophy from disuse of the muscles involved in normal killing and consumption of prey. "Changes in the skull which would be accepted as of specific or possibly of generic value in wild animals from different regions are thus produced in the life of a single individual within from five to seven or eight years, almost as rapidly as if by mutation."

Colyer's [1936] analyzes of 1,236 wild-collected felids revealed only 6% with any type of dental anomaly. None of the 17 cheetahs he examined showed dental abnormality. In our study, the fact that all four cases of advanced FPE found in museum skull specimens were from zoo-raised animals, and that FPE has not been found in any of the wild-killed specimens, strongly supports

the idea that FPE has a direct relationship to the conditions characteristic of the captive environment.

Possible Genetic Contribution

The genetic supposition is based on the fact that irregularity in size, shape, or absence of teeth can be inherited [Tiecke et al, 1959]. All of the affected animals in our study showed some degree of malocclusion, macrodontia, or partial anodontia. Case 1 with absent premolars may have been the result of genetic factors and all of her offspring are being watched for similar abnormalities. FPE may also prove to be a genetic condition that predisposes an individual to the disorder with the actual defect manifesting itself later, depending upon various environmental conditions.

In our study, approximately 86% of live cheetahs with FPE were part of a single shipment from SW Africa in 1970 or their descendants (Fig. 5). Only one animal of 40 from a similar shipment in 1972 developed FPE, which may suggest a genetic factor present in the first group, although the corresponding dietary data may be more revealing of the actual cause.

The recent studies of O'Brien et al [1981] show that wild cheetah populations have extremely low levels of genetic variation, equivalent to at least 20 generations of sib mating! It is difficult to conceive that a defect of the magnitude of FPE is solely of genetic origin and yet appears in so few generations of captive breeding.

CONCLUSIONS

The profile of an apparent development and/or genetic oral-nasal defect labeled focal palatine erosion (FPE) has been described. The exact etiological origin of this defect remains to be determined. If FPE proves to be of genetic origin, the implications for a captive breeding program may be significant. If it is developmental in origin, the management questions may be equally significant.

It is necessary to examine many more live cheetahs, especially those in the wild, before more absolute conclusions can be reached. Our conclusions to date are as follows:

1. Focal palatine erosion medial to the upper first molars appears to be a self-inflicted traumatic disorder associated with abnormal size or position of the lower first molars in cheetahs.
2. In ALL cheetahs, there is normal anatomic indentation of the palatine mucosa in this general area, apparently to accommodate the distal cusp tip of the lower first molar.
3. Focal palatine erosion ranges from the slight loss of palatal pigmentation with inflammatory cellulitis to a large oral-nasal bony defect extending through the palatine bone resulting in osteonecrosis and noma.

4. Insufficient wear and atrophy from disuse of the masticatory apparatus from lack of proper dietary stimulation is believed to be a major cause of FPE.

5. Heritability may be a factor since all but two animals were part of, or offspring of, cheetahs shipped from SW Africa in 1970 (although these animals were also fed a commercially prepared soft diet).

6. Particles of foreign matter and food debris which lodge in the focal palatine defect result in localized infection and further tissue damage.

7. This disorder has been found exclusively in captive cheetahs fed a soft, commercially prepared diet with occasional rabbit or chicken supplement.

REFERENCES

Buchanan, W.; Sehgal, P.; Bronson, R.T.; Rodger, R.F.; Horton, J.E. - Noma in a nonhuman primate. *ORAL SURGERY, ORAL MEDICINE, ORAL PATHOLOGY* 52(1):19-22, 1981.

Colyer, F. - *VARIATION AND DISEASES OF THE TEETH OF ANIMALS*, 36. London, John Bale, 1936.

Corruccini, R.S.; Beecher, R.M. - Occlusal variation related to soft diet in a nonhuman primate. *SCIENCE* 218:74-76, 1982.

Fagan, D.A. - Diet consistency and periodontal disease in exotic carnivores. *PROCEEDINGS OF THE AMERICAN ASSOCIATION OF ZOO VETERINARIANS*, 1980a.

Fagan, D.A. - The pathogenesis of dental disease in carnivores. *PROCEEDINGS OF THE AMERICAN ASSOCIATION OF ZOO VETERINARIANS*, 1980b.

Hollister, N. - *SOME EFFECTS ON ENVIRONMENT AND HABIT ON CAPTIVE LIONS*. No. 2196. *Proceedings of U.S. National Museum*. Vol. 53, pp. 177-193, with plates 22-25, Washington, Government Printing Office, June 1, 1917.

Howard, I.D.; Bush, M.; Wildt, D.; Brand, D.J.; Ebedese, H.; van Dyk, A.; Meltzer, P. - Preliminary reproductive physiology studies on cheetahs in South Africa. (An unpublished manuscript). Washington, D.C., National Zoological Park, 1981.

Jones, M.L. Zoological Society of San Diego - *CAPTIVE HISTORY OF THE CHEETAH *Acinonyx jubatus* (Schreber, 1776)*. Winston, OR., 1981 Cheetah Conference.

Levesque, G.; Demirjian, A.; Tanguay, R. - Sexual dimorphism in the development, emergence,

- and agenesis of the mandibular third molar. JOURNAL DENTAL RESEARCH 60(19): 1735-1741, 1981.
- Marshall, D. - Radiographic correlation of hand, wrist, and tooth development. DENTAL RADIOGRAPHY AND PHOTOGRAPHY 49(3): 51-72, 1976.
- Melhop, P. - THE EFFECTS OF CAPTIVE REARING ON THE MORPHOLOGY OF CAR NIVORES. Snowbird, UT, Host: Brigham Young University. A.S.M. 62nd Annual Meeting, June 20-24, 1982.
- O'Brien, S.J.; Wildt, D.E.; Simonson, J.M.; Brand, D.J.; Ebedes, H.; van Dyk, A.; Meltzer D.; Simmons, L.G.; Bush, M. - On the extent of genetic variation of the African cheetah, *Acinonyx jubatus*.. AMERICAN ASSOCIATION OF ZOO VETERINARIANS, 1981.
- Page, R.C.; Schroeder, - H.E. PERIODONTITIS IN MAN AND OTHER ANIMALS. New York Carger, p. 277, 1982.
- Smuts, G.L.; Anderson, I.L.; Austin, I.D. - Age determination of the African lion (*Panthera leo*). JOURNAL ZOOLOGY LONDON 185:115-146 1978.
- Spolnik, K.J.; Maxwell, D.R.; Patterson, S.S.; Kleit, S.A.; Cockerill, E.M. - Dental radiographic manifestations of end-stage renal disease. DENTAL RADIOGRAPHY AND PHOTOGRAPHY 54(2):21-31, 1981.
- Tiecke, R.W.; Stuteville, O.H.; Calanera, J.C. - PATHOLOGIC PHYSIOLOGY OF ORAL DISEASE. St. Louis, C.V. Mosley, 1959.
- Zontine, W.J. - Canine dental radiology radiographic and development. JOURNAL AMERICAN VETERINARY RADIOLOGY SOCIETY 16(31):75-83. 1975